



## Surgical Management of Impacted Canines: A Literature Review and Case Presentations

Bassam M Kinaia<sup>1\*</sup>, Kiran Agarwal<sup>2</sup>, Brandon Bushong<sup>3</sup>, Natasha Kapoor<sup>4</sup>, Kristyn Hope<sup>5</sup>, Filip Ambrosio<sup>6</sup> and Maanas Shah<sup>7</sup>

<sup>1,5,6</sup>Department of Periodontology and Dental Hygiene, University of Detroit Mercy School of Dentistry, USA

<sup>2,4,7</sup>Department of Periodontology, Private Practice Limited to Periodontics and Dental Implants, USA

<sup>7</sup>Department of Periodontology, Hamdan Bin Mohammad College of Dental Medicine, United Arab Emirates

### Abstract

It has been well reported in the literature that proper development of the canine teeth plays a major role in esthetics as well as in establishing proper dental arch form. When canines are impacted, they can present significant functional and esthetic dilemmas to the patient and clinician. Therefore, proper management of impacted teeth is important to achieve long-term success, functionally and esthetically. The current article describes the development, incidence, etiology and diagnosis of the impacted canine. It highlights the steps required for proper clinical and radiographic examinations and surgical intervention selection based on the literature available. A series of clinical cases are used to highlight the appropriate surgical intervention to obtain predictable outcomes.

**Keywords:** Canine exposure; Impacted tooth; Periodontal; Esthetics; Surgery

### Introduction

When teeth fail to erupt into the oral cavity normally and are impacted, it can affect the dental arch form leading to esthetic and functional challenges. The most commonly impacted teeth are third molars followed by canines [1]. Impacted canines generally present a challenge to the clinician attempting to align the dentition naturally. Surgical intervention is often required to expose the impacted canine; a procedure that must be planned carefully to optimize esthetic and functional outcomes. Complications may include uneven gingival height or contour, asymmetrical clinical crown length, relapse of surgical exposure or damage to adjacent teeth [2]. Therefore, proper exposure of the impacted canines should be sensibly selected to facilitate treatment and achieve proper esthetic and functional results. Understanding development, incidence and etiology of the impacted canine is important to reach a proper diagnosis and facilitate treatment planning to select the appropriate surgical intervention. This article reviews canine impactions and surgical interventions based on the position of the impacted canine supported by clinical case presentations.

### Development

Canines are important teeth in the development of the maxillary and mandibular dentition [3]. The canine tooth germ begins development at 4-5 months and is located very high in the anterior wall of the maxillary sinus, under the floor of the orbit. It is positioned above the root of the lateral incisor until the crown is calcified [4]. Canine crown calcification occurs at the age of one, and it moves below the orbit by the age of three. At age 5-6 years, the crown tip is at the level of the floor of the nose, and calcification is complete [5]. Eruption occurs around 11 years of age and it takes approximately 2-3 years for completion of root development. Thus, the root is completely formed at approximately 13.5 years [6]. The maxillary canine generally travels on a mesial path until it reaches the distal aspect of the lateral incisor root. At this location it uprights to a vertical position and eruption is guided by the root of the lateral incisor. The latter has been referred to as the "Guidance Theory" which proposes that the distal aspect of the lateral incisor root guides the canine into normal position [7].

### Incidence

The maxillary canine is considered the second most frequent tooth to be impacted, while the mandibular third molar is the most common [1]. The incidence reported varies between 0.8% to 2.8% for the maxillary canines and 0.2% for the mandibular canines [8-11]. Unilateral impaction is five times more common than bilateral cases and the left side is slightly more affected than the

### OPEN ACCESS

#### \*Correspondence:

Bassam M Kinaia, Department of Periodontology and Dental Hygiene, University of Detroit Mercy School of Dentistry, Detroit, Michigan, USA, Tel: 13134946944;

E-mail: kinaia@udmercy.edu

Received Date: 20 Sep 2016

Accepted Date: 25 Oct 2016

Published Date: 14 Nov 2016

#### Citation:

Kinaia BM, Agarwal K, Bushong B, Kapoor N, Hope K, Ambrosio F, et al. Surgical Management of Impacted Canines: A Literature Review and Case Presentations. *J Dent Oral Biol*. 2016; 1(3): 1012.

**Copyright** © 2016 Kinaia BM. This is an open access article distributed under the Creative Commons Attribution License, which permits unrestricted use, distribution, and reproduction in any medium, provided the original work is properly cited.

**Table 1:** Recommended surgical technique for canine exposure, as it relates to the position of impaction.

Canine Position	Open Technique		Closed Technique
	Gingivectomy	Apically Positioned Flap	
Labial – Palatal of Alveolus	Labial	Middle or Labial	Palatal
Apical – Coronal to MGJ	Coronal to MGJ	At MGJ	Apical to MGJ
Keratinized Gingiva	Adequate	Inadequate	Mucosa
Mesial – Distal	Between lateral and premolar	Distal to lateral incisor	Mesial to lateral incisor

right [12]. Females are more 2.5 times more likely to have impacted canines than males Dachi et al. [13] in 1961 found the incidence to be 1.17% in females and 0.51% in males. With regard to the position of canine impaction within the arch, the maxillary canine is found in a palatal impaction 85% of the time, versus being in a buccal impaction position (15%) [8,14]. Therefore, early detection, review of family history, clinical examination by age 9-10 years, as well as thorough radiographic assessment is essential in the diagnosis of canine impactions.

**Etiology**

The maxillary canine develops in the highest area of the face relative to the rest of the dentition. Therefore, it has an extended development period and the longest path of eruption in the permanent dentition before it reaches its final position. This, amongst other factors, may contribute to the relative increase in frequency of canine impaction [15]. Another etiologic factor may be arch length discrepancy leading to a tooth erupting buccally when crowding is present resulting in a labial rather than palatal impaction [10,16]. On the other hand when adequate arch space is present the canine erupts palatally in 85% of cases. Other etiologic factors include the possibility that palatal impaction is a result of trauma to the maxillary anterior region at an early stage of development [17]. The “Guidance Theory” proposes that the distal aspect of the lateral incisor root guides the canine into normal position. Problems may arise when a peg lateral is present or a lateral incisor is congenitally missing which may lead to a higher incidence of palatally displaced canines [18]. Moreover, congenitally missing lateral incisors occur about 35% of the time where they can play an important role in canine impaction incidence [19]. Becker et al. [7] in 1981, in a large group of palatally displaced canines, found that 5.5% of cases had congenitally missing lateral incisors. Therefore, it is suggested that when the lateral incisor is missing, it may interfere with the guidance of the canine along its path of eruption.

**Diagnosis**

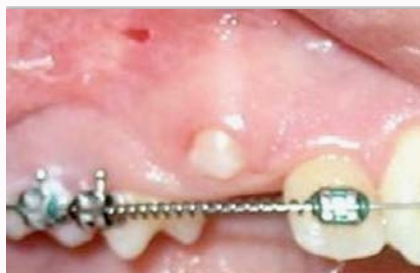Clinical and radiographic assessments are essential tools in evaluating the presence and location of the impacted canine. The clinician must consider the amount of space in the dental arch, morphology and position of adjacent teeth, contours of the bone, mobility of the teeth as well as a radiographic assessment to determine the position of the impacted canine in three dimensions [4]. Clinically, palpation of the canine prominence is important to aid in determining the presence of the permanent canine. When the primary canine is retained past its normal age of exfoliation, accompanied by the absence of a canine bulge, this may be an indication of atypical canine eruption. In addition, the clinician should further investigate asymmetry in the canine bulge, aberrant eruption sequence, and distal tipping or migration of the lateral incisors as alternative indicators for canine impaction [20-22]. Radiographically, the use of lateral, occlusal, panoramic or periapical radiographs have been reported. Williams et al. [23] 1981, recommends taking lateral and frontal

radiographs in patients with a Class I malocclusion to determine canine impaction position. In addition, occlusal radiographs are a useful supplemental aid in diagnosing impacted canine location [4,21,24]. Panoramic radiographs can also assist in early diagnosis of impacted canines [25]. Periapical radiographs are usually more useful in determining the position of impaction compared to other two dimensional radiographic imaging techniques. Changing the horizontal angle of the X-ray tube head while maintaining the film position aids in establishing the position of the impacted canine using the SLOB rule (SLOB: Same Lingual and Opposite Buccal) [24]. Currently, the use of three-dimensional radiographic imaging such cone beam computed tomography (CBCT) is considered to be the diagnostic tool that indicates the most accurate position of the impacted canine in relation to adjacent teeth and it has been suggested to be the standard of care [26,27].

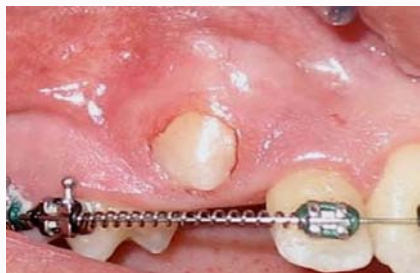**Methods**

**Surgical Intervention Recommendations:** Thorough clinical and radiographic evaluation is crucial to determine the appropriate method of surgical intervention to expose the impacted canine. Many factors must be taken into consideration including confirmation of the impacted canine presence, length and stage of root formation, inclination of the long axis of the tooth, canine apical-coronal position relative to the mucogingival junction (MGJ), buccal-lingual position of the tooth, quantity of bone covering the impacted tooth, and proximity to adjacent teeth [26]. Therefore, clinical and radiographic evaluation of these factors must be carefully assessed before selecting a surgical intervention approach. Based on the position of the impacted canine, it can be treated with an open or closed technique [28]. Labial impactions are usually treated by an open surgical intervention such as gingivectomy or apically positioned flap depending on the impacted tooth position [2,28]. Palatal impactions are generally treated by early removal of the deciduous canine and/or with a closed technique [28,29].

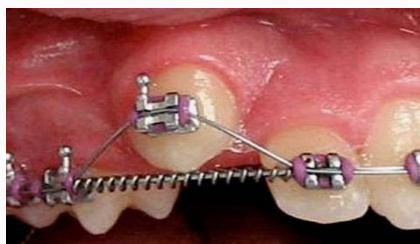To simplify treatment options, Kokich et al. [28] [30]. Suggested careful evaluation of four criteria related to tooth position within the alveolar bony housing before exposing the impacted canine [28,30]. The first criterion looks at the labial-palatal position of the impacted canine. When there is labial impaction, the treatment of choice is an open technique (gingivectomy or apically positioned flap). While impaction in the mid-alveolus requires an open or closed technique and a palatal impaction is usually treated using a closed technique. The second criterion evaluates the impaction position relative to the MGJ in an apical-coronal dimension. When the majority of the impacted crown is positioned coronal to the MGJ, then gingivectomy open technique can be done. If the crown is located at the MGJ level, an apically repositioned flap is done. When the crown is apical to the MGJ, a closed technique is generally utilized. The third criterion involves the evaluation of the amount of keratinized gingiva (KG) mainly with facial impactions. When there is abundance of keratinized



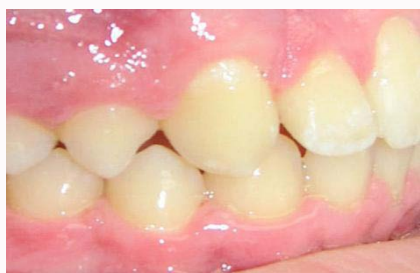**Figure 1:** Case 1: Labial view showing inadequate eruption of maxillary right canine.



**Figure 2:** Case 1: Gingivectomy performed maintaining adequate keratinized gingiva.



**Figure 3:** Case 1: Placement of orthodontic bracket and successful movement of the tooth into the arch.



**Figure 4:** Case 1: Final photo post orthodontics with maxillary right canine in occlusion.

gingiva and the impacted canine is positioned relatively close to the MGJ, a gingivectomy procedure is recommended. However if there is inadequate KG, an apically repositioned flap or closed technique is suggested. The fourth and final criterion evaluates the mesial-distal position of the canine relative to the lateral incisor. If the canine crown is positioned distal to the mesial aspect of the lateral incisor, an open technique is performed. If the crown is positioned mesial to the lateral incisor, a closed technique is advisable to erupt the tooth palatally first and once it is erupted, then bring it into the ideal position. This will aid in reducing any unwanted adverse effects such as damage to adjacent roots or bone loss around the palatally impacted canine

[31,32]. The aforementioned criteria are summarized in Table 1.

**Surgical Techniques: Open vs. Closed Technique:** Clinical and radiographic assessment at an early age is important. Evaluation should start as early as eight years of age, with follow-ups every six months until the age ten [20]. This is important in the management of the impacted permanent canine as extraction of the primary canine could facilitate the eruption of the permanent one before it is destined for palatal impaction [22,31,33]. Further, early exposure can potentially prevent the formation of a cyst which may result in resorption of the roots of adjacent teeth [31,32]. Therefore, surgical uncovering is recommended for functional and esthetic benefits.

Esthetically, it is recommended to move the impacted canine through keratinized gingiva and to avoid eruption through non-keratinized mucosal tissues [2]. If the impacted canine is close to or at the MGJ, an apically positioned flap or gingivectomy allows the impacted canine to erupt through KG leading to a more esthetic outcome [31]. When minimal KG is present, a free gingival graft can be performed to increase the width and thickness of the keratinized tissue for optimal esthetic results [21]. With either the closed or open technique, the tooth is surgically exposed and an orthodontic bracket or button with a gold chain is placed and immediate gentle forces are applied to bring the tooth into the correct arch position.

## Case Presentation

In the current case series, multiple surgical techniques were carefully selected based on the position of the impacted canines. Treatment modalities varied from closed to open technique such as the use of apically positioned flap or gingivectomy following the recommendations highlighted in Table 1. The suggested guidelines mentioned in this review paper aim to simplify the decision making for treatment of impacted canines.

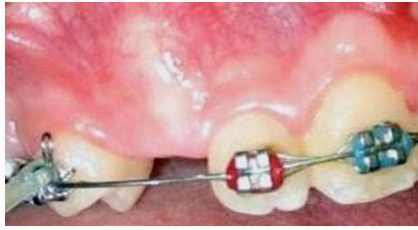### Case 1

A 12-year-old Caucasian male with an unremarkable medical history presented with an impacted right maxillary canine (#1-3). The majority of the anatomical crown was positioned coronal to the MGJ with adequate amount of KG and mesial-distal arch space (Figure 1). The patient was referred for clinical crown exposure to allow proper placement of the orthodontic bracket. Based on the impacted canine position, an open technique via gingivectomy was recommended and the patient and guardian consented to treatment. A gingivectomy was performed to expose the clinical crown, allowing placement of the orthodontic bracket (Dentsply, York, PA, USA) (Figure 2). The patient returned to the treating orthodontist after the one-week follow-up where active force was applied to initiate the desired tooth movement (Figure 3). The tooth was erupted into occlusion and debonded. The 1 year follow up shows stable periodontium with wide zone of keratinized gingiva present (Figure 4).

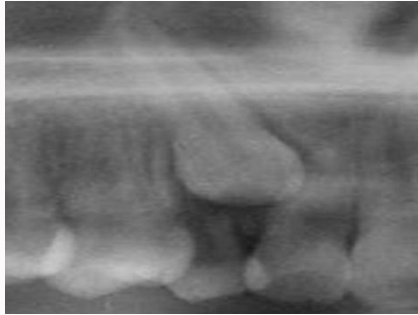### Case 2

A 12-year-old Caucasian male with an unremarkable medical history was referred for exposure of impacted right maxillary canine (#1-3). The primary canine was extracted approximately 6 weeks prior to exposure consultation. The clinical examination revealed a labial bulge with thin soft tissue coverage. Radiographically, tooth #1-3 was positioned apical to the MGJ approaching the distal surface of the lateral incisor (Figures 5 and 6). An open surgical technique was recommended using an apically positioned flap and the patient and guardian consented to treatment. A paracostal incision including

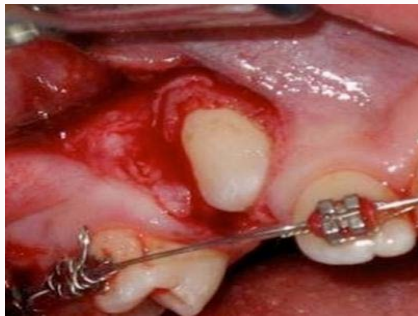



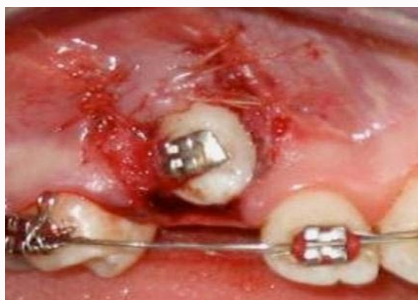**Figure 5:** Case 2: Facial view showing a bulge and thinning soft tissue overlaying the maxillary right canine.



**Figure 6:** Case 2: Radiographic presentation of impacted maxillary right canine with close proximity to the lateral incisor.

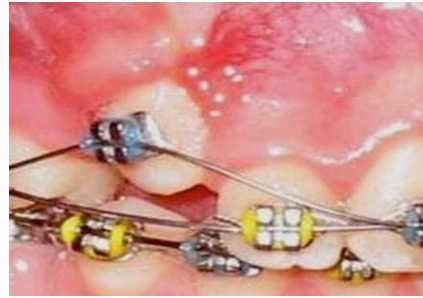

**Figure 7:** Case 2: Facial view showing open technique to expose #1-3, utilizing vertical incisions.

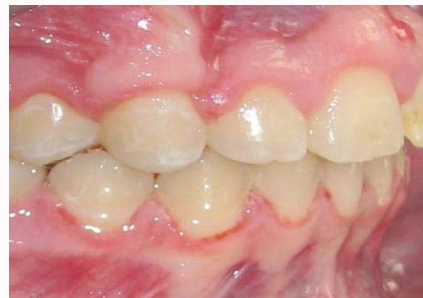

**Figure 8:** Case 2: Facial view showing placement of orthodontic bracket with apically positioned flap.

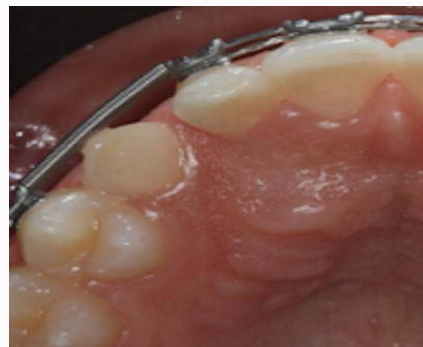adequate amount of keratinized gingiva and utilizing two vertical incisions positioned 1 mm from the adjacent lateral incisor and first premolar was performed. A full-thickness facial flap was reflected apically and facial bone was removed to expose the anatomical crown of tooth #1-3. Maintaining an adequate band of KG facially, an orthodontic bracket (Dentsply, York, PA, USA) was placed using a composite resin material (Ivoclar Vivadent, Amherst, NY, USA) and the flap was sutured apically with 4-0 resorbable sutures (Vicryl,



**Figure 9:** Case 2: Four weeks post-surgical exposure showing coronal advancement of the previously impacted canine into the arch.



**Figure 10:** Case 2: Final photo post orthodontics with maxillary right canine in occlusion.

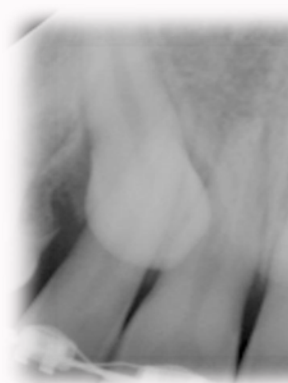

**Figure 11:** Case 3: Occlusal view showing retained maxillary right primary canine.

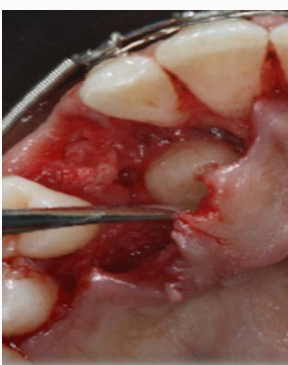
Medline Industries, IL, USA) (Figures 7 and 8). After four weeks of healing, adequate clinical crown exposure was achieved and the patient continued orthodontic treatment successfully (Figure 9). The tooth was in occlusion with stable periodontium at the 1 year follow up (Figure 10).

**Case 3**

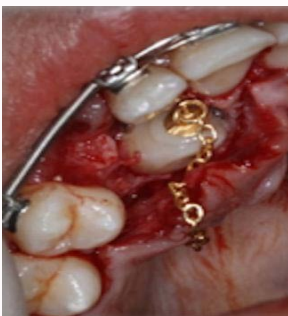A 15-year-old Caucasian male with an unremarkable medical history was referred for exposure of tooth #1-3. Upon clinical evaluation, the primary canine was present and tooth #1-3 was positioned apical to the MGJ resting on the distal aspect of the lateral incisor (Figure 11 and 12). A closed approach was discussed and agreed upon as the treatment of choice. The primary canine was extracted, and a sulcular incision was performed on the adjacent teeth. A full thickness palatal flap reflection was performed, the overlying bone removed and the permanent canine exposed (Figure 13). An orthodontic button and chain (Dentsply, York, PA, USA) were attached to #1-3 using a composite resin material (Ivoclar Vivadent, Amherst, NY, USA) similar to case #2 (Figure 14). The flap was then



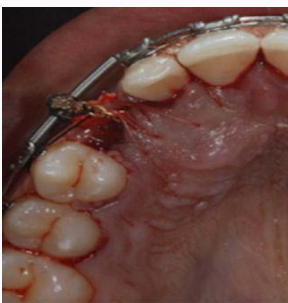**Figure 12:** Case 3: Radiographic presentation of impacted maxillary right canine with close proximity to the central incisor.



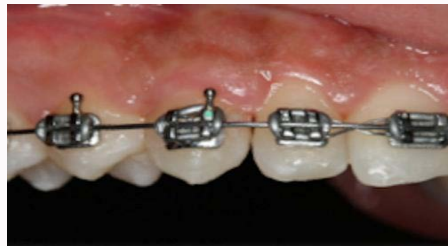
**Figure 13:** Case 3: Occlusal view showing extracted primary canine and palatal exposure of permanent canine.



**Figure 14:** Case 3: Occlusal view showing placement of orthodontic button and gold chain.



**Figure 15:** Case 3: Occlusal view showing repositioned palatal flap using closed surgical exposure.



**Figure 16:** Case 3: Labial view showing full eruption of impacted canine six months post-exposure.

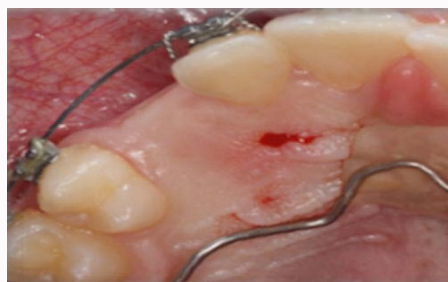re-positioned to cover the impacted canine and the gold chain exiting through the extraction site and secured to the orthodontic wire using a non-resorbable suture (Silk, Ethicon, Cincinnati, OH, USA) (Figure 15). The desired orthodontic position was achieved after six months of healing (Figure 16).

**Case 4**

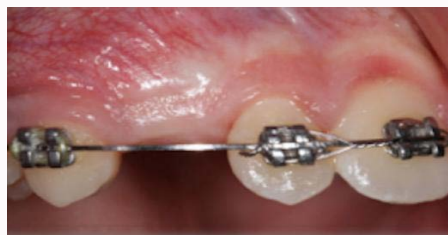A 12-year-old Caucasian male with an unremarkable medical history was referred for exposure of #1-3. Clinically, there was no soft tissue prominence present; suggestive of a mid-alveolar impaction (Figure 17 and 18). Radiographically, the impacted canine appeared to be centered mesiodistally between the lateral incisor and the first premolar (Figure 19). A closed surgical technique was recommended and the patient and guardian consented to treatment. A paracostal incision in the impacted canine region with sulcular incisions on the adjacent teeth was performed maintaining adequate KG facially. A full-thickness flap was reflected and an orthodontic button and chain were placed (Figure 20). The flap was then re-positioned to cover the impacted canine and the gold chain (Dentsply, York, PA, USA) secured using a non-resorbable suture (Silk, Ethicon, Cincinnati, OH, USA) (Figure 21). Orthodontic movement was initiated one-week post-surgery and the tooth successfully repositioned after four months of healing (Figure 22).

**Discussion**

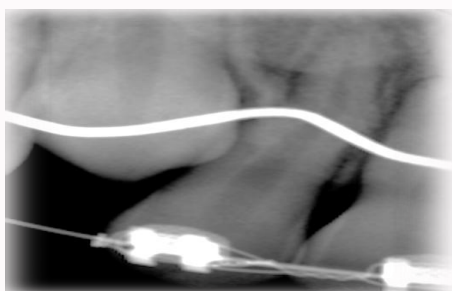
Canine impactions play a significant role in the treatment planning of comprehensive orthodontic care. Understanding the



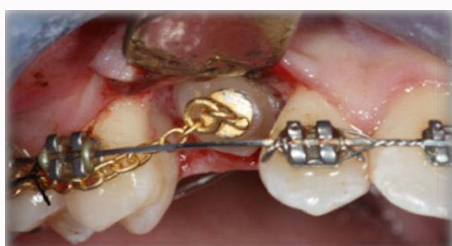**Figure 17:** Case 4: Occlusal view of impacted maxillary right canine.



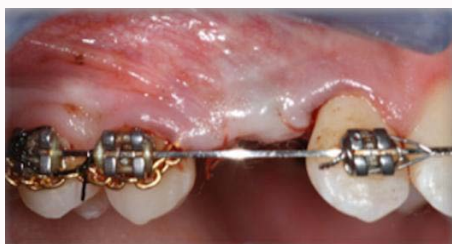**Figure 18:** Case 4: Facial view showing adequate keratinized gingiva.



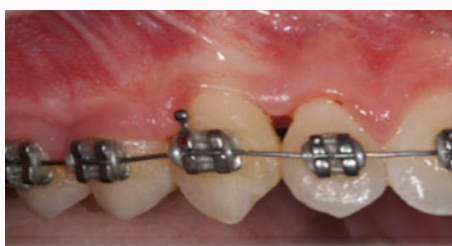**Figure 19:** Case 4: Radiographic presentation of impacted canine positioned in the center between lateral incisor and first premolar.



**Figure 20:** Case 4: Labial view showing placement of orthodontic button and gold chain.



**Figure 21:** Flap repositioned over surgically exposed #1-3.



**Figure 22:** Clinical appearance of #1-3, following two months of forced eruption.

development and etiology of canine impactions is important to diagnose the impacted canine and determine an appropriate treatment plan. Therefore, a multi-disciplinary team consisting of orthodontist and periodontist is often involved to determine proper diagnosis, sequence, and course of surgical treatment to achieve adequate esthetic and functional results. Careful clinical and radiographic examinations are essential to determine the position of the impacted canine and select the correct surgical interventions to facilitate treatment and achieve favorable results. Clinically, the patient may present with a bulge or thinning of the overlying mucosa may be seen, indicating a labial impaction. Cone beam computed tomography or conventional radiographs are often used as diagnostic tools to determine the location of the impaction. Thereafter, assessment of the impacted canine in a bucco lingual, apico coronal as well as amount

of keratinized gingiva and position relative to the mucogingival junction position aid in determining if an open (gingivectomy or apically positioned flap) or closed surgical intervention should be selected as the course of treatment.

## Conclusion

In the current case series, different surgical interventions were employed based on the location of the impacted canine allowing proper exposure to proceed with planned orthodontic treatment. Esthetically pleasing results were achieved with adequate keratinized gingiva and without infection or surgical complication. The surgical interventions used to expose the impacted canines resulted in satisfactory and stable functional and esthetic results with stable periodontium in the presented cases.

## References

1. Bass TB. Observations on the misplaced upper canine tooth. *Dent Pract Dent Rec.* 1967; 18: 25-33.
2. Vermette ME, Kokich VG, Kennedy DB. Uncovering labially impacted teeth: apically positioned flap and closed-eruption techniques. *Angle Orthod.* 1995; 65: 23-32.
3. Zasciurinskiene E, Bjerklin K, Smaliene D, Sidlauskas A, Puisys A. Initial vertical and horizontal position of palatally impacted maxillary canine and effect on periodontal status following surgical-orthodontic treatment. *Angle Orthod.* 2008; 78: 275-280.
4. Moss JP. The unerupted canine. *Dent Pract Dent Rec.* 1972; 22: 241-248.
5. Broadbent B. Ontogenic development of occlusion. *Angle Orthod.* 1941; 11: 223-241.
6. Proffit William R, Fields Henry W, Sarver David M. *Contemporary orthodontics.* St. Louis, Mo.: Mosby Elsevier. 2007.
7. Becker A, Smith P, Behar R. The incidence of anomalous maxillary lateral incisors in relation to palatally-displaced cuspids. *Angle Orthod.* 1981; 51: 24-29.
8. Ericson S, Kurol J. Radiographic assessment of maxillary canine eruption in children with clinical signs of eruption disturbance. *Eur J Orthod.* 1986; 8: 133-140.
9. Shah RM, Boyd MA, Vakil TF. Studies of permanent tooth anomalies in 7,886 Canadian individuals. I: impacted teeth. *Dent J.* 1978; 44: 262-264.
10. Thilander B, Jakobsson SO. Local factors in impaction of maxillary canines. *Acta Odontol Scand.* 1968; 26: 145-168.
11. Thilander B, Myrberg N. The prevalence of malocclusion in Swedish schoolchildren. *Scand J Dent Res.* 1973; 81: 12-21.
12. Shapira Y, Kufnec MM. Early diagnosis and interception of potential maxillary canine impaction. *J Am Dent Assoc.* 1998; 129: 1450-1454.
13. Dachi SF, Howell FV. A survey of 3, 874 routine full-month radiographs. II. A study of impacted teeth. *Oral Surg Oral Med Oral Pathol.* 1961; 14: 1165-1169.
14. Rayne J. The unerupted maxillary canine. *Dent Pract Dent Rec.* 1969; 19: 194-204.
15. Coulter J, Richardson A. Normal eruption of the maxillary canine quantified in three dimensions. *Eur J Orthod.* 1997; 19: 171-183.
16. Jacoby H. The etiology of maxillary canine impactions. *Am J Orthod.* 1983; 84: 125-132.
17. Brin I, Solomon Y, Zilberman Y. Trauma as a possible etiologic factor in maxillary canine impaction. *Am J Orthod Dentofacial Orthop.* 1993; 104: 132-137.
18. Becker A, Zilberman Y, Tsur B. Root length of lateral incisors adjacent



- to palatally-displaced maxillary cuspids. *Angle Orthod.* 1984; 54: 218-225.
19. Stellzig A, Basdra EK, Komposch G. The etiology of canine tooth impaction--a space analysis. *Fortschr Kieferorthop.* 1994; 55: 97-103.
  20. Ngan P, Robert Hornbrook, Bryan Weaver. Early Timely Management of Ectopically Erupting Maxillary Canines. *Semin Orthod.* 2005; 11: 152-163.
  21. Nagan PW, Wolf T, Kassoy G. Early diagnosis and prevention of impaction of the maxillary canine. *ASDC J Dent Child.* 1987; 54: 335-338.
  22. Bishara SE. Impacted maxillary canines: a review. *Am J Orthod Dentofacial Orthop.* 1992; 101: 159-171.
  23. Williams BH. Diagnosis and prevention of maxillary cuspid impaction. *Angle Orthod.* 1981; 51: 30-40.
  24. Ericson S, Kurol J. Radiographic examination of ectopically erupting maxillary canines. *Am J Orthod Dentofacial Orthop.* 1987; 91: 483-492.
  25. Lindauer SJ, Rubenstein LK, Hang WM, Andersen WC, Isaacson RJ. Canine impaction identified early with panoramic radiographs. *J Am Dent Assoc.* 1992; 123: 91-92, 95-97.
  26. Mah J, Enciso R, Jorgensen M. Management of impacted cuspids using 3-D volumetric imaging. *J Calif Dent Assoc.* 2003; 31: 835-841.
  27. Ericson S, Kurol J. CT diagnosis of ectopically erupting maxillary canines--a case report. *Eur J Orthod.* 1988; 10: 115-121.
  28. Kokich VG. Surgical and orthodontic management of impacted maxillary canines. *Am J Orthod Dentofacial Orthop.* 2004; 126: 278-283.
  29. Ericson S, Kurol J. Early treatment of palatally erupting maxillary canines by extraction of the primary canines. *Eur J Orthod.* 1988; 10: 283-295.
  30. Kokich VG, Mathews DP. Surgical and orthodontic management of impacted teeth. *Dent Clin North Am.* 1993; 37: 181-204.
  31. Kuflinec MM, Shapira Y. The impacted maxillary canine: II. Clinical approaches and solutions. *ASDC J Dent Child.* 1995; 62: 325-334.
  32. Wise RJ. Periodontal diagnosis and management of the impacted maxillary cuspid. *Int J Periodontics Restorative Dent.* 1981; 1: 56-73.
  33. Kuflinec MM, Shapira Y. The impacted maxillary canine: I. Review of concepts. *ASDC J Dent Child.* 1995; 62: 317-324.